

INTERNATIONAL JOURNAL OF AYURVEDA360



**AYURVEDA
360**

**PEER-REVIEWED
BIMONTHLY JOURNAL**



| www.ayurveda360.in/journal

ISSN

PRINT:

3048-7382

ONLINE:

3048-7390

2025

VOLUME 1

ISSUE 5

MARCH-

APRIL

CASE STUDY

Access this article online



Scan Here
Website:
www.ayurveda360.in/journal

ISSN
PRINT: 3048-7382
ONLINE: 3048-7390
Bimonthly Journal

Publication History:

Submitted: 08-March-2025
Revised: 04-April-2025
Accepted: 14-April-2025
Published: 15-April-2025



How to cite this article:

Singh, D., Malsariya, S., & Bharathi K.(2025). *Ayurvedic Management of Oligohydramnios: A Case Report on the Use of Ksheerabasti for Enhancing Amniotic Fluid Volume*. *International Journal of Ayurveda360*, 1(5), 421–429. <https://doi.org/10.63247/3048-7390.vol.1.issue5.16>

Ayurvedic Management of Oligohydramnios: A Case Report on the Use of *Ksheerabasti* for Enhancing Amniotic Fluid Volume

Dr. Deeksha Singh* Dr. Swati Malsariya** Prof. (Dr.) Bharathi K.***

*PG Scholar, Department of Prasuti Tantra evam Stree Roga, National Institute of Ayurveda, Jaipur, <https://orcid.org/0009-0001-5373-1216>

**Ph.D. Scholar, Department of Prasuti Tantra evam Stree Roga, National Institute of Ayurveda, Jaipur.

***Professor & HOD, Department of Prasuti Tantra evam Stree Roga, National Institute of Ayurveda, Jaipur.

Abstract

Introduction:

Oligohydramnios, characterized by a decrease in amniotic fluid, can lead to complications such as fetal growth restriction and placental insufficiency. The condition is typically managed with medical interventions, but Ayurvedic approaches offer promising alternatives for improving amniotic fluid volume.

Methods:

A 36-week primigravida patient presented with decreased fetal movement and an Amniotic Fluid Index (AFI) of 6-7 cm. The patient was treated with *Ksheerabasti*, an Ayurvedic therapy involving rectal administration of a combination of *Shatavari*, *Ashwagandha*, *Gokshura*, *Vidarikanda*, *Yashtimadhu*, and *Phalaghrita*.

Results:

After one week of *Ksheerabasti* treatment, the patient showed significant improvement in amniotic fluid volume, with an increase in AFI to within normal range. The patient also reported improved fetal movement.

Discussion:

This case demonstrates the potential of Ayurvedic therapies like *Ksheerabasti* in managing oligohydramnios. The use of medicinal herbs may play a role in restoring amniotic fluid volume.


Further research is necessary to explore the long-term efficacy and safety of Ayurvedic treatments for this condition.

Keywords: Oligohydramnios, *Ksheerabasti*, Amniotic Fluid Index, *Shatavari*, *Ashwagandha*, *Gokshura*

Address for Correspondence:

Dr. Deeksha Singh, PG Scholar, Department of Prasuti Tantra evam Stree Roga, National Institute of Ayurveda, Jaipur, Email Id: sdeeksha274@gmail.com

Licensing and Distribution

	This work is licensed under a Creative Commons Attribution 4.0 International License . (https://creativecommons.org/licenses/by/4.0/) You are free to share, copy, redistribute, remix, transform, and build upon this work for any purpose, even commercially, provided that appropriate credit is given to the original author(s) and source, a link to the license is provided, and any changes made are indicated.
---	--

Publisher Information

This journal is published under the tradename **Ayurveda360**, which is registered under UDYAM-KR-27-0044910.

Introduction

Amniotic fluid plays a critical role in fetal development, providing space for movement, aiding in gastrointestinal and lung maturation, and preventing umbilical cord compression. Oligohydramnios is characterized by a significant reduction in amniotic fluid, with less than 200 ml of fluid, an Amniotic Fluid Index (AFI) below 5 cm, a maximum vertical pocket of fluid measuring less than 2 cm, and a 2D pocket less than 15 cm. This condition increases the risk of fetal distress, umbilical cord compression, meconium-stained liquor, operative deliveries, and stillbirth at term. Symptoms commonly include reduced fetal movement, which can be correlated with Ayurvedic concepts such as *Manda Spandana* of *garbha* (decreased fetal movement) and *Anunatakushita* (reduced fetal growth). These are akin to the Ayurvedic conditions *Garbhashosha* (reduced amniotic fluid or fetal distress) and *Gabhakshaya* (fetal malnutrition), as described by Acharya Sushruta.

In Ayurveda, the treatment of oligohydramnios at term follows the principles for managing *Garbhashosha* and *Gabhakshaya*, aiming to promote fetal health and ensure normal delivery. Modern medicine suggests the use of arginine to improve amniotic fluid levels, whereas Ayurveda recommends nourishing therapies, such as *Medhyaanna* for *Garbakshya* [1] and

Brimhaniyapaya (milk-based therapies) for *Garbhashosha* [2]. In this study, a combination of *Shatavari*, *Ashwagandha*, *Gokshura*, *Vidarikanda*, *Yashtimadhu*, and *Phalaghrita* was used in the form of *Ksheerbasti* to treat oligohydramnios, promoting fetal growth and improving amniotic fluid levels without adverse side effects.

Patient Information

A 25-year-old primigravida patient presented to the OPD of the Department of Prasutitantra and *Streeroga* at the National Institute of Ayurveda, Jaipur, on July 15, 2024, at 4.5 months of amenorrhea. Ultrasound confirmed a single live intrauterine pregnancy with normal growth parameters. The patient was advised regular follow-up visits, a balanced diet rich in fluids, iron, and calcium, along with routine antenatal ultrasounds. Subsequent ultrasounds showed adequate amniotic fluid and normal parameters.

However, due to dietary negligence, the patient reported a decrease in fetal movement starting the night of November 13, 2024. She presented the following morning with an ultrasound showing a single live intrauterine fetus at 36 weeks and 1 day, with reduced amniotic fluid (6-7 cm) and a biophysical profile of 6/8, with a fetal heart rate of 136 bpm. The patient was treated with Ayurvedic management, including *Shatavari*, *Ashwagandha*, *Gokshura*, *Vidarikanda*,

Yashtimadhu, and *Phalaghrita* in the form of *Ksheerbasti*.

- Nil

Past Surgical History:

- Nil

Family History:

- Not significant

Allergic History:

- None

Menstrual History:

- Age of Menarche: 13 years
- Duration of Menses: 3-4 days
- Interval of Menses: 28-30 days
- Last Menstrual Period: 05/03/2024
- Expected Date of Delivery: 10/12/2024

Obstetric History:

- Gravida 1, Para 0, Live Birth 0, Abortion 0 (G1 P0 L0 A0)
- Married Life: 1 year

Antenatal Investigation:

- All blood and urine investigations normal

Timeline

The patient was advised a course of *Ksheerbasti* (*Shatavari*, *Gokshura*, *Mulethi*, *Vidarikanda*, *Ashwagandha*, and *Phalaghrita*) for seven days. After the course, another ultrasound was recommended to assess changes in amniotic fluid volume.

Method of preparation and route of administration of ksheerabasti

To prepare *Ksheerbasti*, a fine powder of *Shatavari*, *Gokshura*, *Mulethi*, *Vidarikanda*, and *Ashwagandha*, each in equal amounts of 5 grams (totaling 25 grams),

Clinical Findings

General Examination:

- General Condition: Good
- Blood Pressure: 100/70 mm Hg
- Pulse Rate: 80/min
- Temperature: 98.3°F
- Height: 5'4"
- Weight: 69 kg
- BMI: 26.3 kg/m²
- Pallor: Absent
- Pedal Edema: Absent

Systemic Examination:

- Digestive System: NAD
- Cardiovascular System: NAD
- Respiratory System: NAD
- Central Nervous System: NAD

Abdominal Examination:

- Fundal Height: 34-36 weeks of gestation
- Fetal Lie: Longitudinal
- Fetal Presentation: Cephalic
- Fetal Heart Rate: 142 bpm
- Uterus: Relaxed

Personal History:

- Appetite: Normal
- Sleep: Disturbed
- Bowel Movements: Clear
- Bladder: Clear
- Addiction: None
- Diet: Vegetarian

Past Medical History:

is boiled with 350 ml of milk (*Ksheera*) and 350 ml of water over mild heat (*Mandagni*) until only the milk remains. After this, *Phalaghrita* (30 ml) is added to the *Ksheerapaka* and mixed thoroughly. The preparation is then filtered through a fine

sieve to remove any solid particles. The resulting lukewarm mixture (350 ml) is administered rectally in the *Nyubja Avastha* (knee-elbow position) with the help of an enema can.

Table No. 1: Schedule of Ksheerbasti Administration

Date	Gestational age	Retained time
14/11/24	36 weeks 0day	15min.
15/11/24	36 weeks 1day	20min.
16/11/24	36 weeks 2days	15min.
17/11/24	36 weeks 3days	15min.
18/11/24	36 weeks 4days	20min.
19/11/24	36 weeks 5day	25min.
20/11/24	36 weeks 6day	15min.

Table No.2.Ultrasonography findings

Before treatment protocol
USG (25/04/24) – Single live intrauterine pregnancy with gestational age 6weeks 5days
USG NT NB Scan (03/06/24) - Single live intrauterine pregnancy with gestational age 12weeks 6days , NT :1.2mm,NB :3.1mm ,FHS – 167 BPM, Placenta -posterior reaching upto os ,Liquor – Adequate
USG LEVEL II(06/08/24) - Single live intrauterine pregnancy with gestational age 21weeks 5days.No gross congenital anomaly seen ,Liquor – Adequate, Placenta -posterior not low lying ,FHS – 148 BPM
USG FWB (14/11/24) - Single live foetus of 36weeks 2days gestational age ,Placenta - posterior upper segment grade III, Liquor – less ,AFI 6 to7cm
After treatment protocol
USG COLOUR DOPPLER (20/11/24) - Single live foetus of 35weeks 6days in cephalic presentation , Liquor – Normal ,AFI 10.12cm , Placenta -posterior away from os grade III

Outcome

Post-treatment, the patient observed a gradual improvement in fetal movements. Each visit showed consistent improvements in fundal height, aligning with the period of amenorrhea. A follow-up ultrasound on 20/11/2024 confirmed a single live fetus of 35 weeks 6 days with an AFI of 10.12 cm, fetal heart rate of 130 bpm, and normal fetal movement. The estimated fetal weight was 2691 +/- 404 gm. This improvement in the

amniotic fluid index and overall fetal health demonstrated the effectiveness of the Ayurvedic intervention.

Discussion

Oligohydramnios is a clinical condition marked by a reduced volume of amniotic fluid, which is crucial for fetal development. In Ayurvedic terms, oligohydramnios is thought to result from the depletion (*Kshaya*) of the *Jaliya-mahabhuta* (water element), which in turn leads to an

imbalance in the body's natural fluid dynamics. This depletion results in conditions like *Garbhashosha* (fetal distress due to reduced amniotic fluid) and *Gabhakshaya* (fetal malnutrition or growth restriction), as described by Acharya Sushruta. These conditions impede the normal development of the fetus and the amniotic fluid that envelops it.

In the classical Ayurvedic approach, the treatment of oligohydramnios is aimed at restoring balance to the *Jalijatva* (water principle) and nurturing the fetus. For managing *Garbhashosha*, Acharya Sushruta recommends *Brimhaniya paya* (milk-based therapies), which nourish the body and enhance the production of amniotic fluid. For *Gabhakshaya*, which refers to fetal growth retardation, *Medhyanna* (nourishing food) is prescribed to improve fetal health and development.

In this study, the combination of *Shatavari*, *Ashwagandha*, *Gokshura*, *Vidarikanda*, *Yashtimadhu*, and *Phalaghrita* was administered in the form of *Ksheerbasti*. This formulation, which possesses *Madhura rasa* (sweet taste), *Madhura vipaka* (sweet post-digestive effect), *Sheeta veerya* (cooling potency), and *Snigdha* and *Guru* (unctuous and heavy qualities), is known to enhance the *Jalijatva*, thereby improving the amniotic fluid volume. Additionally, *Ksheerbasti* pacifies *Apana Vata* (the downward-moving Vata dosha), which is responsible for the

expulsion of waste and the regulation of bodily fluids. By enhancing uteroplacental blood flow, *Ksheerbasti* promotes the production of amniotic fluid.

Furthermore, the *Snigdha* (unctuous) and *Sheeta* (cooling) properties of the formulation nourish and hydrate the body, helping to balance fluid levels within the uterus and support uterine health. The rejuvenating (*Rasayana*) properties of the herbs improve maternal and fetal nourishment, enhancing vitality and overall health. The amino acids and flavonoids present in these herbs may help neutralize free radicals, thereby protecting the fetus from oxidative stress, promoting its growth, and maintaining normal fluid volume in the uterus.

The observed improvement in fetal movement and the increase in the Amniotic Fluid Index (AFI) from 6-7 cm to 10.12 cm post-treatment is a promising outcome that suggests the efficacy of Ayurvedic interventions like *Ksheerbasti* in managing oligohydramnios. The significant enhancement in amniotic fluid volume and fetal well-being demonstrates the potential of Ayurvedic medicine in the management of pregnancy-related conditions. Further research with larger sample sizes and long-term follow-up studies would be valuable to confirm these findings and validate the role of Ayurvedic treatments in obstetric care.

Figure 1: Before treatment: Ultrasonography reports

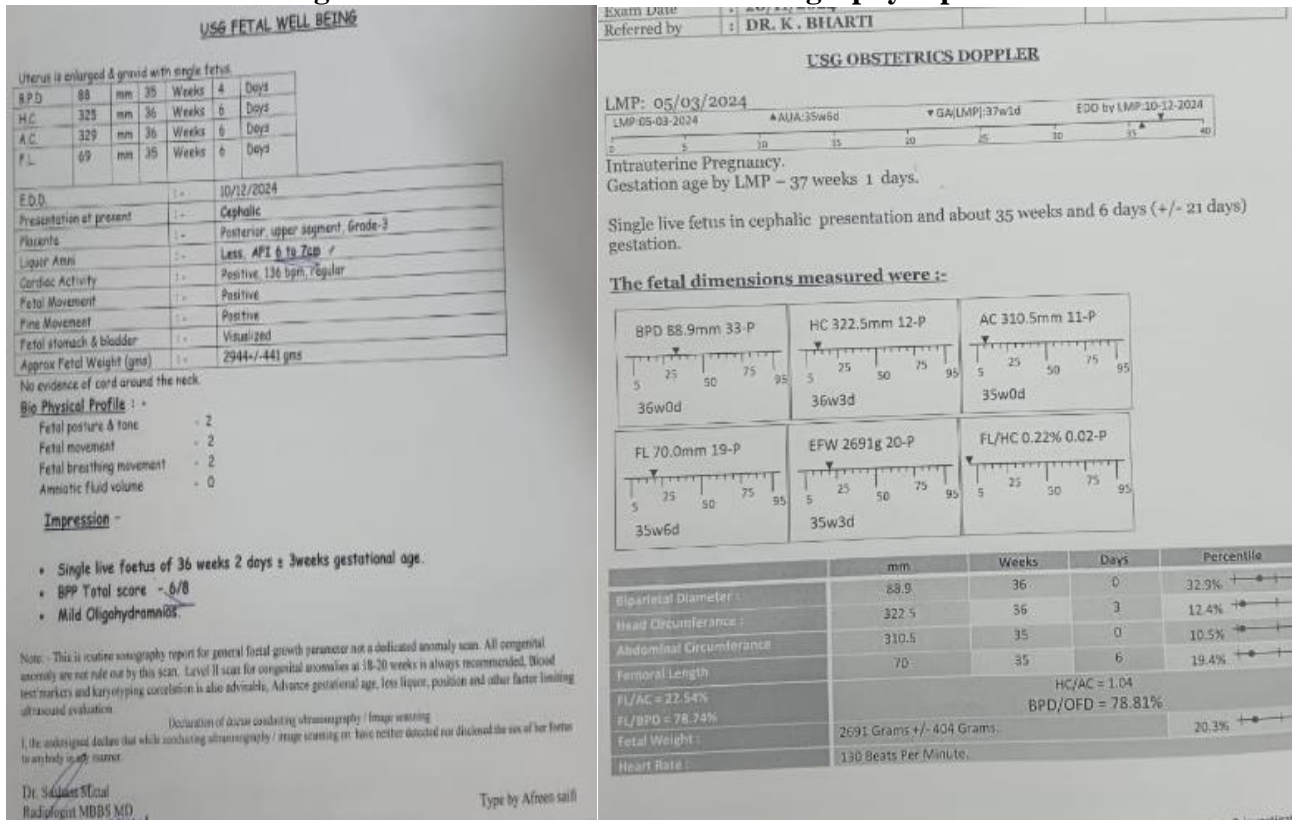


Figure 2: After treatment: Ultrasonography reports

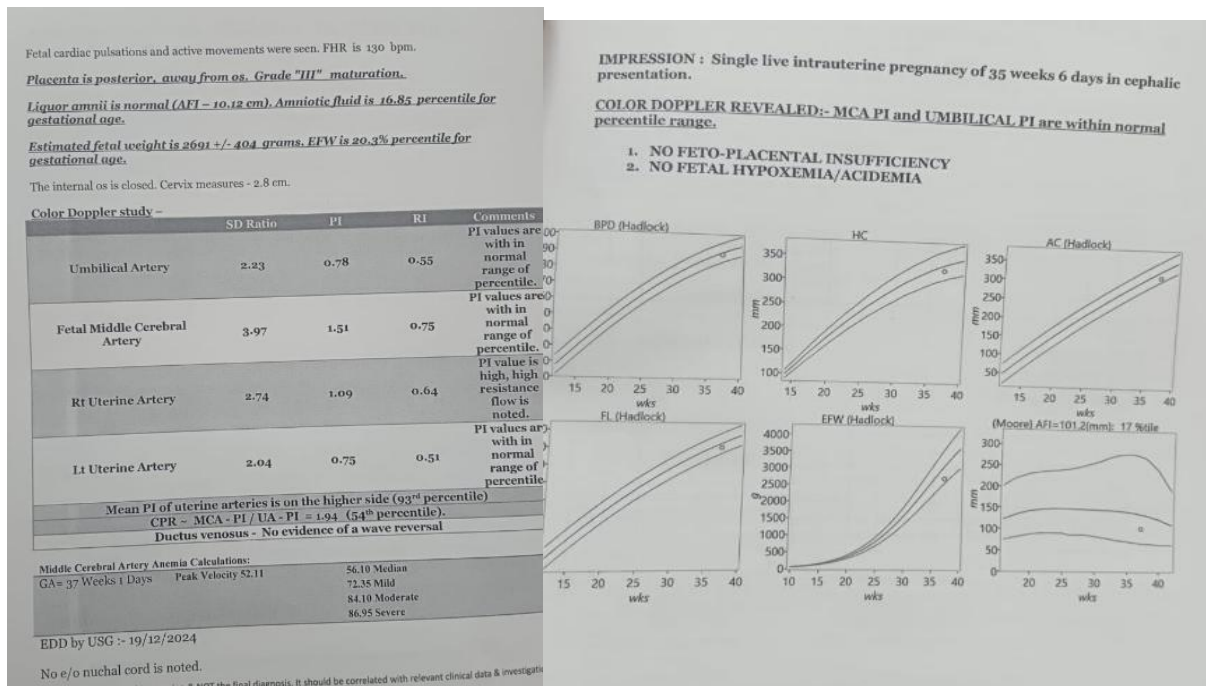


Table No. 3. Depicting ingredients

S.N	Drug	Rasa	Guna	Veerya	Vipaka	Doshagh nata	Karma
1.	Shatavari [3]	Madhu-ra, Tikta	Guru, Snigdha,	Sheeta	Madhura	Vaatpitta shamaka	Rasayana, Garbhaposhka , Balya , Pushtidayaka and Medhya. [4,5]
2.	Ashwaga ndha [6]	Tikta, Kashaya, Madhu-ra	Snigdha, Laghu	Ushna	Madh- ura	Kaphavat ashamak	Rasayana, vajikaran, Balya , Brimhan,
3.	Vidarikan da [7]	Madhura	Guru, Snigdha,	Sheeta	Madh- ura	Vaatpitta shamaka	Vrisya, Rasayana, Balya, Stanyaja nan, vajikaran
4.	Mulethi [8]	Madhura	Guru, Snigdha,	Sheeta	Madh- ura	Vaatpitta shamaka	Rasayana , Balya, vajikaran , Vaatanulomana
5.	Gokshura [9]	Madhura	Guru, Snigdha,	Sheeta	Madh- ura	Vaatpitta shamaka	Garbhsthapana, Balya, Vrisya , Vaatanulomana

Conclusion

The administration of *Ksheerbasti* has demonstrated promising results in the management of oligohydramnios by effectively enhancing amniotic fluid levels. This Ayurvedic treatment works by nourishing the reproductive system, improving maternal hydration, and balancing the Vata dosha, which collectively support fetal health. Clinical observations from this case suggest that *Ksheerbasti*, when used as part of an integrative approach to care, can help alleviate complications associated with reduced amniotic fluid, such as fetal growth restriction and umbilical cord compression. The significant improvement in both fetal movement and amniotic fluid index observed in this patient highlights the potential of Ayurvedic treatments in managing pregnancy-related conditions. However, further clinical trials with larger sample sizes

and more rigorous methodologies are essential to substantiate these findings and establish standardized protocols for the use of *Ksheerbasti* in obstetric care. Continued research is needed to validate the long-term efficacy and safety of this treatment, ensuring its broader application in clinical practice.

Consent for Publishing

The patient provided informed consent for the publication of this case report, including the use of their medical information and ultrasound images, ensuring confidentiality and understanding of the content being shared.

Conflict of Interest

The authors declare that there are no conflicts of interest associated with this case report, and no financial or personal relationships influenced the study's design or results.

References:

1. Shastri AD. Shonitvarnaneyamadhyayam verse 16. In: Sutra Sthana Susruta Samhita, Chaukambha San-skrit Sansthan, Varanasi; 2012.p. 77.
2. Shastri AD. Garbhinivyakaranamshaariram verse 62. In: Sharir Sthana Susruta Samhita, Chaukambha San-skrit Sansthan, Varanasi; 2012.p. 112.
3. Sharma PV. Dravya Guna Vigyan, Part II. 2nd ed. Chaukhamba Bharti Academy, Varanasi; 2005.p. 563.
4. Dr JLN Shastri, editor. Illustrated Dravya Guna, (Vol II). Varanasi: Chowkambha orientalia ; Reprint2012;p. 540-542.
5. Dr Gyanendra Pandey, editor. Dravyaguna Vijnana (Vol III). Varanasi: Chowkambha krishnadas academy; Reprint 2004;p.434-437
6. Sharma PV. Dravya Guna Vigyan, Part II. 2nd ed. Chaukhamba Bharti Academy, Varanasi; 2005.p. 764.
7. Sharma PV. Dravya Guna Vigyan, Part II. 2nd ed. Chaukhamba Bharti Academy, Varanasi; 2005.p. 641.
8. Sharma PV. Dravya Guna Vigyan, Part II. 2nd ed. Chaukhamba Bharti Academy, Varanasi; 2005.p. 254.
9. Sharma PV. Dravya Guna Vigyan, Part II. 2nd ed. Chaukhamba Bharti Academy, Varanasi; 2005.p. 632.